

Magnetic Resonance Imaging (MRI)

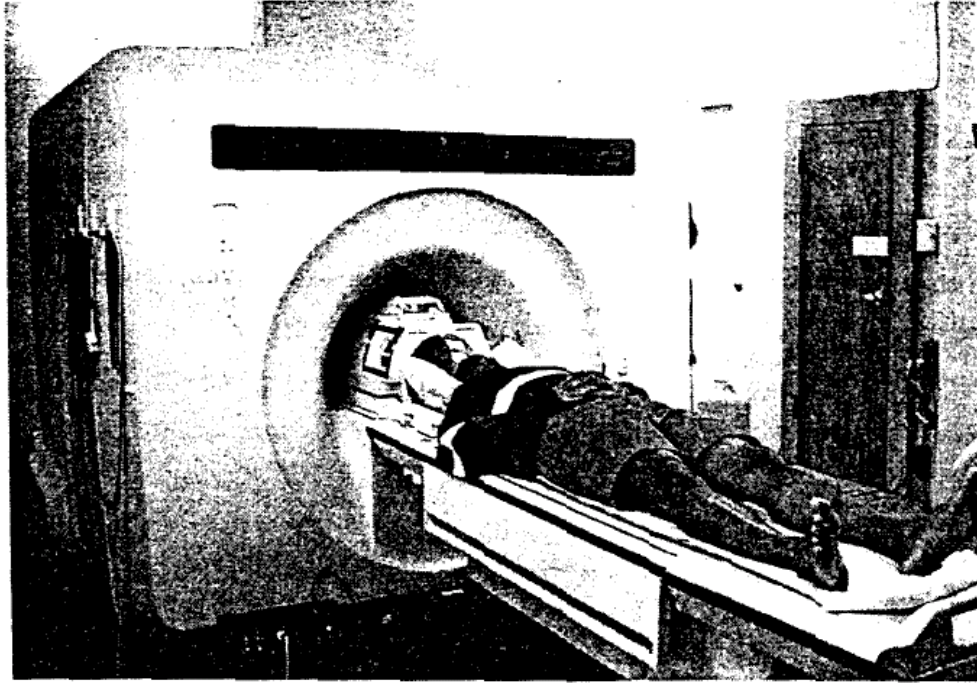

Figure 16.1. A 1.5-T, 100-cm-diameter bore NMR system for human clinical use. The table automatically moves the subject into the magnet.

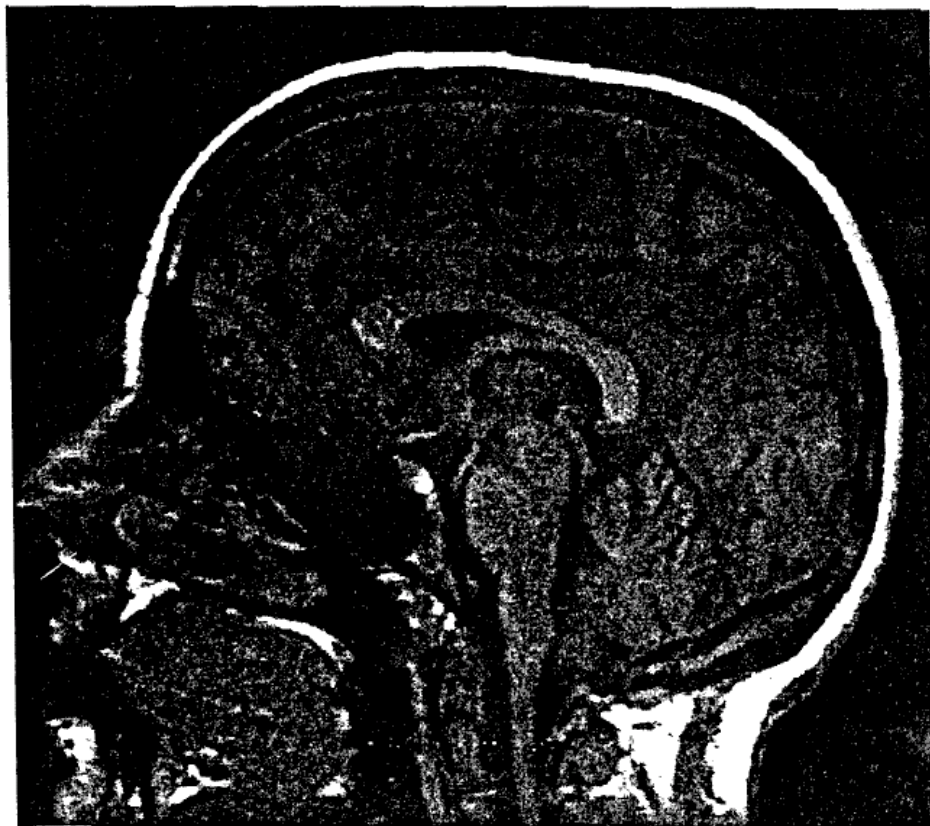


Figure 16.6. Sagittal (side) proton NMR image of a human head. (Courtesy of Terrance A. Campbell.)